



**DATE PRESENTING CLINICAL SIGNS**

3.5.26

**PATIENT**

Friztal Chamberlian

**SPECIES**

Feline

**BREED**

DSH

**SEX**

MN

**AGE**

12.1.11

**WEIGHT**

8.52lbs

History: Recheck echo. Longstanding history of heart murmur. Chronic intermittent vomiting does well on PR diet, transdermal maropitant, B12 and probiotics. Previous ultrasound showed chronic pancreatic remodeling, age-related kidney change, non-obstructive nephroliths, inflammatory bowel disease pattern and prominent mesenteric lymph nodes. Recent history of vomiting and hematuria and was seen at ER. X-ray show nephrolith in R kidney. Mild progression of kidney disease on labs. Chronic low-grade hypercalcemia. Stress hyperglycemia in clinic, has normal BG at home. Grade 2-3/6 heart murmur.

-Pertinent abnormal PE/Chem/CBC/UA Results (2/27/26) Crea 2.7, BUN 39, PSL 37, Glu 238, neu 11.5 K, hematuria. 2/21/26 (VEG) Crea 2.2, BUN 40, neu 11.5, hematuria.

-CXR (2/27/26): increased sternal contact of heart with nephrolith in R kidney, no obvious masses.

-Sedation used: Not required to complete full diagnostic ultrasound.

-Pertinent previous ultrasound results (2025 MML): Essentially normal with a physiologic murmur.

-STAT: Not requested.

-Imaging performed by: Andi Parkinson, BS, RDMS.

**ECHOCARDIOGRAM FINDINGS**

2D, m-mode, color flow and doppler imaging is available. The left ventricular wall is mild to moderately hypertrophied with regions of irregularity. There is a mildly hyperechoic endocardium consistent with fibrosis and ventricular remodeling. Mild papillary muscle hypertrophy. The right ventricle is subjectively normal in size and morphology. There is mild left atrial enlargement present. No right atrial enlargement present. Normal RVOT velocity. There is systolic anterior motion (SAM) of the mitral valve present, with a severely elevated LVOT velocity (dynamic profile). There is mild eccentric mitral regurgitation present secondary to SAM. No other obvious valvular regurgitation is present. There is no pericardial effusion noted. No pleural effusion appreciated. No cardiac tumors visualized.

**CARDIAC CHART**

**INTERPRETED BY**

Maggie Machen Lamy,  
DVM, DACVIM  
(Cardiology)

**HOSPITAL NAME**

Everhart VH

**REFERRING VET**

Dr. Notarangelo

**INVOICE**

47121

FELINE CARDIAC PARAMETERS	BODY WEIGHT (kg)	HR (BPM)	IVSd (cm) (Moise, Pipers)	LVIDd (cm) (Moise, Pipers)	LVWd (cm) (Moise, Pipers)	FS (%)	EF (%)
NORMAL PARAMETER	-----	150-240	3.5-0.55	<2 (mean 1.5)	3.5-0.55	35-67	80-100
PATIENT	3.9	190	0.66	1.1	0.62	47	90
FELINE CARDIAC PARAMETERS	LA/AO (Boon)	LA/AO HEART BASE (Swe) (Abbott)	LA 2D short axis Base view (cm) (Abbott)		LVOT VEL (m/s)	RVOT VEL (m/s)	E max (m/s)
NORMAL	<1.5	<1.3	<1.2		<1.6	<1.3	<0.9
PATIENT	NM	1.5	1.5		>6.0	1.0	NM

Adapted from June Boon, Veterinary Echocardiography, 1998  
Abbott J & MacLean H JVIM 2006;20: 111-119, Moise et al. Am J Vet Res 47:1476, 1986. Pipers et al. Am J Vet Res 40:882, 1979.

### **INTERPRETATION OF THE FINDINGS & FURTHER RECOMMENDATIONS**

Given that the previous evaluations have essentially been normal, the changes seen here are considered development of organic disease. The likely diagnosis is hypertrophic obstructive cardiomyopathy (HOCM). This indicates LV hypertrophy (mild to moderate in this case) with a dynamic LVOT obstruction (SAM) and secondary MR. There is mild left atrial dilation, indicating the risk of spontaneous CHF and/or a thrombotic event, while currently low, may be elevated in the future. A screening BP and T4 are recommended every 6 months, as both can exacerbate disease. No additional issues are seen.

While no medications have been shown to definitively alter long term outcome at this stage of disease, atenolol is often initiated to decrease the outflow obstruction. Given the degree of hypertrophy and mild LA dilation, consider initiate at this time as below. If there is difficulty medicating at home, an alternative approach would be closely monitoring for progression in the next 6 months. Discussion with the owner is advised. *Regarding the newly available drug Felycin:* This medication has not been tested in cats with a significant obstruction (i.e. HOCM) and is not recommended in this case.

Long term prognosis is guarded for subclinical HOCM, with a great deal of variability in rate of progression. The REVEAL study showed that approximately 7% of asymptomatic cats with HOCM will develop CHF or a cardiogenic thrombus within 1 year, 20% within 5 years, and ~30% within 10 years. Close monitoring for progressive LA dilation going forward will help better predict long term outcome.

Anesthetic risk is considered mildly elevated; however, judicious fluid administration is advised if needed with careful monitoring to screen for fluid overload. A reasonable protocol includes opioid/benzodiazepine premedication, propofol induction, isoflurane maintenance. Avoid ketamine, telazol, acepromazine and Dexdomitor. Additionally, drugs that stimulate heart rate should be avoided unless clinically necessary (glycopyrrolate, atropine).

Risk for complication with steroid or fluid use typically follows LA dilation, which in this case is mildly elevated. If needed, monitoring of RR/RE is advised particularly in the initiation phase.

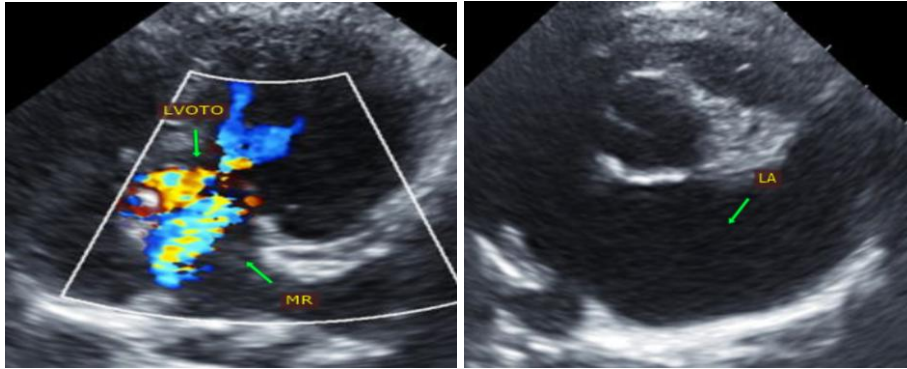
Monitor at home for any respiratory signs or blood clot events (neurologic change, paralysis, etc.) in the future.

### **PLAN**

Screening BP/T4 every 6 months. Administer titrating dose of atenolol: 25mg tablets; Give ¼ tab once daily. Recheck heart rate in 1-2 weeks with target stressed rate of 140-160bpm 12-24 hours post-administration. Increase as needed until target reached.

Recommend recheck echocardiogram in 6 months to assess for progression, sooner if clinical issues arise.

## IMAGES



**The information and recommendations provided are based on the images presented by the referring veterinarian. No evaluation can be communicated regarding pathology that was not visible in the image/video clips provided.**

Thank you for this referral. This report was generated using transcription software, and minor dictation errors may be present. If the clinical or image interpretation does not parallel your findings or if I can be of any further assistance, please contact me.

**Maggie Machen Lamy, DVM**  
**Diplomate of the American College of Veterinary Internal Medicine (Cardiology)**  
**info@sonopath.com**